



**PATIENT**

Jerry McSherry

**SPECIES**

Feline

**BREED**

Domestic Short Hair

**SEX**

MN

**AGE**

2003

**WEIGHT**

6.7lbs

**INTERPRETED BY**

Maggie Machen  
Lamy, DVM, DACVIM  
(Cardiology)

**HOSPITAL NAME**

Timonium Animal  
Hospital

**REFERRING VET**

Dr. Kauder

**INVOICE**

21433

**DATE**

10/8/21

**PRESENTING CLINICAL SIGNS**

History: Heart murmur (2+ years) and increasing ProBNP (currently 1005, was 636 Nov 2020)  
Otherwise no signs of heart disease.

-Pertinent abnormal PE/Chem/CBC/UA Results: ProBNP 1005, T4: 4.4, FT4 2.9.

-Current medications: Methimazole 2.5mg BID for past 8 months, just increased on 10/3/21 to 5mg am, 2.5mg pm.

-Blood pressure: 10/8/21= 204 systolic, 122 diastolic, MAP 135. 9/29/21= 161 systolic, 117 diastolic MAP 128.

-Sedation used: Sedation not required.

-STAT: Not requested.

**ELECTROCARDIOGRAPHIC FINDINGS**

A six lead ECG is available at both 25 and 50mm/s; 2mm/mV. The average heart rate is 188bpm. The rhythm is sinus in origin, with a p for every QRS complex and vice versa. The P wave morphology is positive with a normal dimension. Normal PR. The QRS is isoelectric. MEA is indeterminate. Isolated VPCs throughout; monomorphic, singles only. No ectopic beats, pauses or dysrhythmias observed.

ECG diagnosis: Normal sinus rhythm with isolated VPCs.

**ECHOCARDIOGRAM FINDINGS**

2D, m-mode, color flow and doppler imaging is available. The left ventricular walls are asymmetric, with a mildly hypertrophied free wall and a borderline septum. There is a diffusely hyperechoic endocardium consistent with fibrosis. Mild papillary muscle hypertrophy. The endocardium also appears remodeled. False tendon. Adequate systolic function. The left atrium is mildly enlarged. No significant mitral regurgitation. No tricuspid regurgitation. The right atrium is normal in size. The right ventricle appears normal (subjective). The mitral valve is normal in structure and mobility. Blood flow through both the LVOT and RVOT are normal in velocity on Spectral; however, a mild RVOTO is suspected on color flow imaging. Trivial AI. No PI. No obvious cardiac tumors identified. No effusions.

**CARDIAC CHART**

FELINE CARDIAC PARAMETERS	BODY WEIGHT (kg)	HR (BPM)	IVSd (cm) (Moise, Pipers)	LVIDd (cm) (Moise, Pipers)	LVWd (cm) (Moise, Pipers)	FS (%)	EF (%)
NORMAL PARAMETER	-----	150-240	3.5-0.55	<2 (mean 1.5)	3.5-0.55	35-67	80-100
PATIENT	3.0	210	0.58	1.6	0.68	68	95
FELINE CARDIAC PARAMETERS	LA/AO (Boon)	LA/AO HEART BASE (Swe) (Abbott)	LA 2D short axis Base view (cm) (Abbott)		LVOT VEL (m/s)	RVOT VEL (m/s)	E max (m/s)
NORMAL	<1.5	<1.3	<1.2		<1.6	<1.3	<0.9
PATIENT	NM	1.4	1.4		1.2	1.5	NM

Adapted from June Boon, Veterinary Echocardiography, 1998  
Abbott J & MacLean H JVIM 2006;20: 111-119, Moise et al. Am J Vet Res 47:1476, 1986. Pipers et al. Am J Vet Res 40:882, 1979.

## INTERPRETATION OF THE FINDINGS & FURTHER RECOMMENDATIONS

Hypertrophic cardiomyopathy is a rule out diagnosis once a patient is deemed euthyroid and normotensive. In a known hyperthyroid with recent thyroid elevation this may be related. Additionally, the blood pressure is elevated yet highly variable and should be reassessed as a possible contributing factor. Regardless, the degree of abnormality is mild with only focal septal thickening noted and mild left atrial enlargement. This would indicate low risk for complication at this time and no cardiac medications are clearly indicated. The murmur is suspected to be due to a dynamic RVOTO which is benign physiologic origin.

The ECG does confirm an arrhythmia, with single ventricular premature contractions (VPCs) noted. VPCs are generated from abnormal conductive or fibrotic tissue in the ventricles of the heart muscle, and even frequent single VPCs will often cause no clinical signs. When sustained however, ventricular tachycardia can lead to symptoms such as lethargy and collapse.

VPCs are a very non-specific finding. They can be primary in origin (a rule out dx), secondary to significant cardiac disease (mild in this study), or be extra-cardiac in origin, i.e., due to pain, stress, inflammation, cancer, GI disease, DIC/sepsis, etc. In a geriatric cat, all differentials should be ruled out. An abdominal ultrasound to monitor for any underlying abnormalities, in addition to full screening lab work.

When assessing VPCs, we must not only consider why they are happening, but if we should treat them. Markers of malignancy are assessed, in addition to patient history and signalment. Based upon what is seen here in addition to the highly sensitive nature of cats to anti-arrhythmic medications, I would not institute therapy at this time. Assuming the patient remains asymptomatic, reassessing the finding periodically through auscultation/ECG monitoring is a reasonable approach.

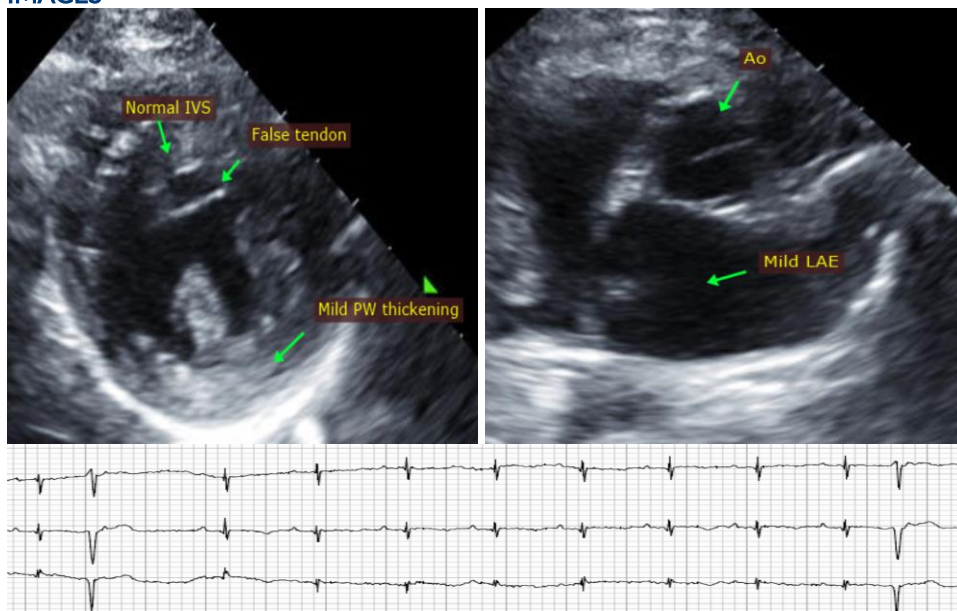
Anesthetic risk is considered moderately elevated due to the arrhythmia, and judicious IV fluid rates are advised to avoid fluid overload. Additionally, drugs that stimulate heart rate should be avoided unless clinically necessary (glycopyrrolate, atropine). Avoid ketamine, telazol, alpha 2 agonists. A reasonable protocol includes opioid/benzodiazepine premedication, propofol induction, isoflurane maintenance. Monitor ECG intra and post-operatively, with careful intervention if ventricular arrhythmias worsen (i.e., sustained VT) and lead to hemodynamic compromise.

## PLAN

Monitor BP and T4 every 6 months. Full systemic evaluation as discussed.

A recheck echocardiogram and ECG are recommended in 6 months to monitor for progression, sooner if any issues arise in the interim.

## IMAGES



**The information and recommendations provided are based on the images presented by the referring veterinarian. No evaluation can be communicated regarding pathology that was not visible in the image/video clips provided.**

Thank you for this referral. This report was generated using transcription software, and minor dictation errors may be present. If the clinical or image interpretation does not parallel your findings or if I can be of any further assistance, please contact me.

**Maggie Machen Lamy, DVM**  
**Diplomate of the American College of Veterinary Internal Medicine (Cardiology)**  
**info@sonopath.com**